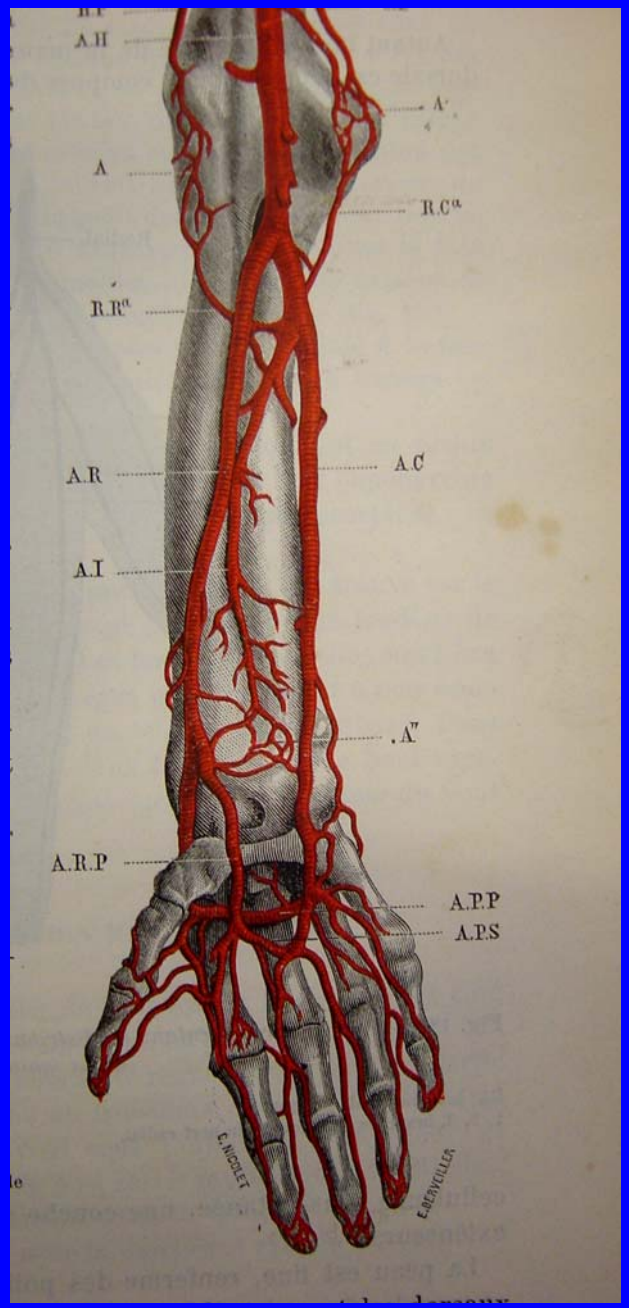
A.H
A
A.R
A.I
A.R.P
A.P.P
A.P.S
E. NICOLET
E. BERVILLER

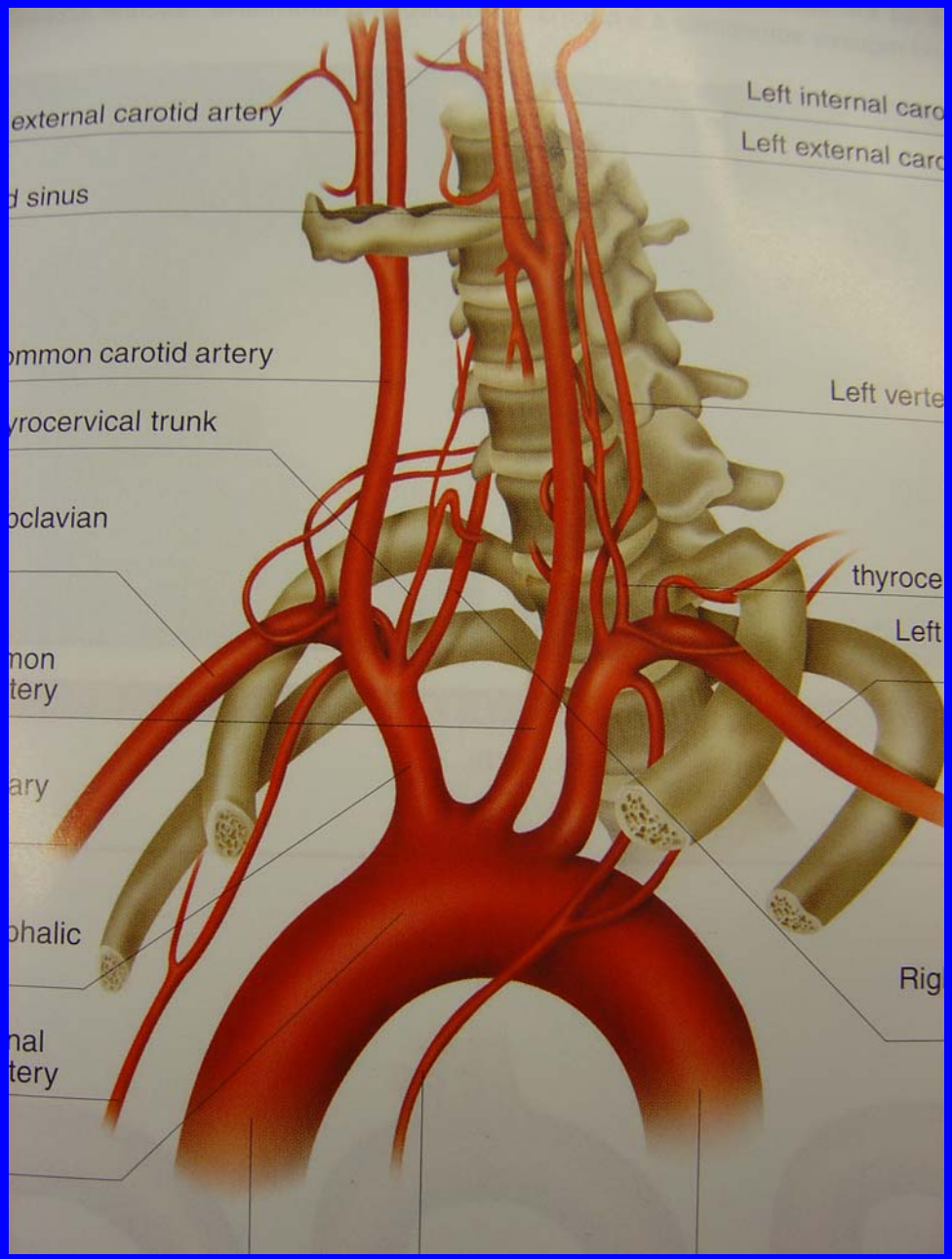
external carotid artery
d sinus
mmon carotid artery
rocervical trunk
oclavian
mon
tery
ary
halic
nal
tery
Left internal caro
Left external caro
Left verte
thyroce
Left
Rig

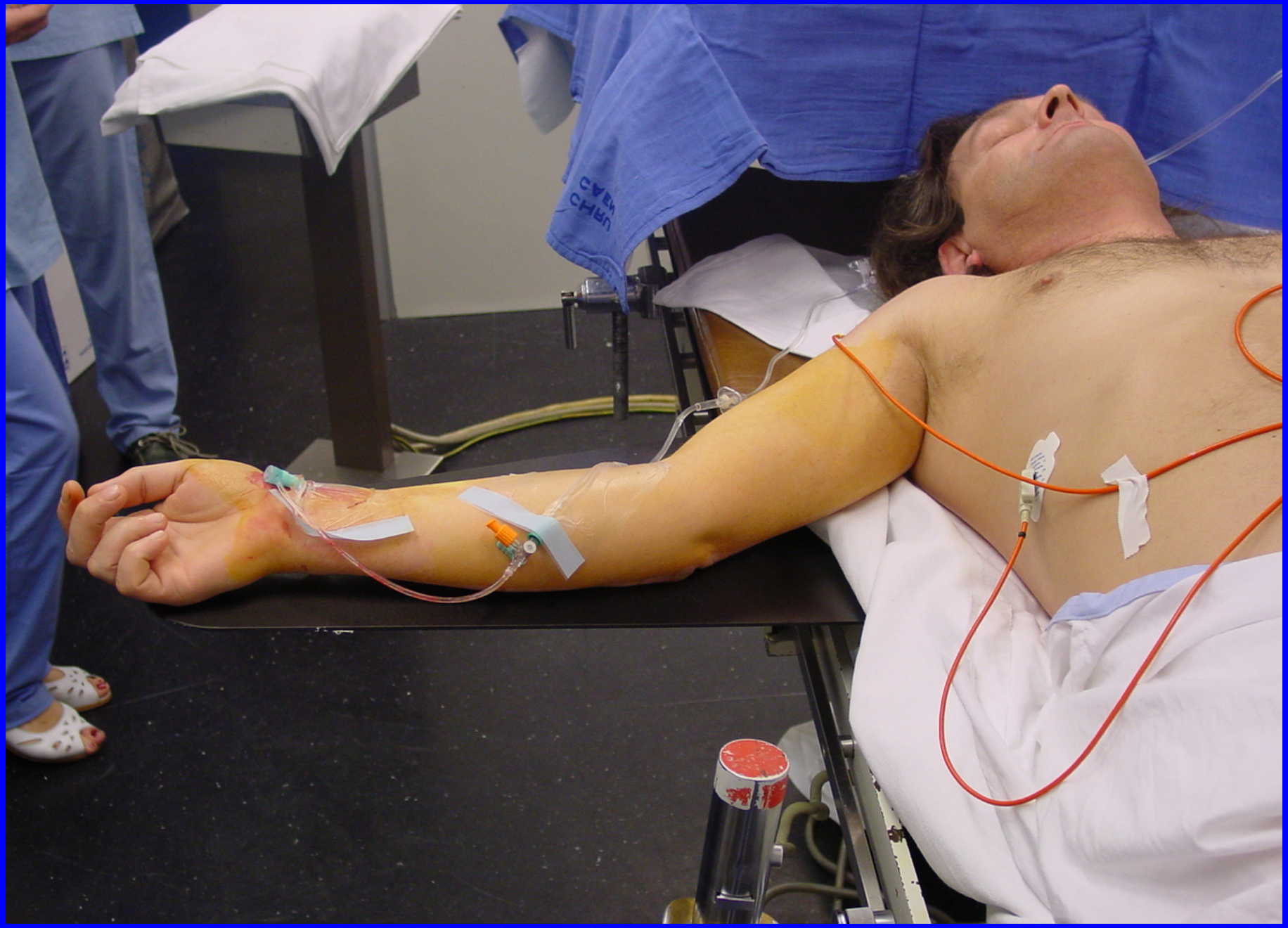

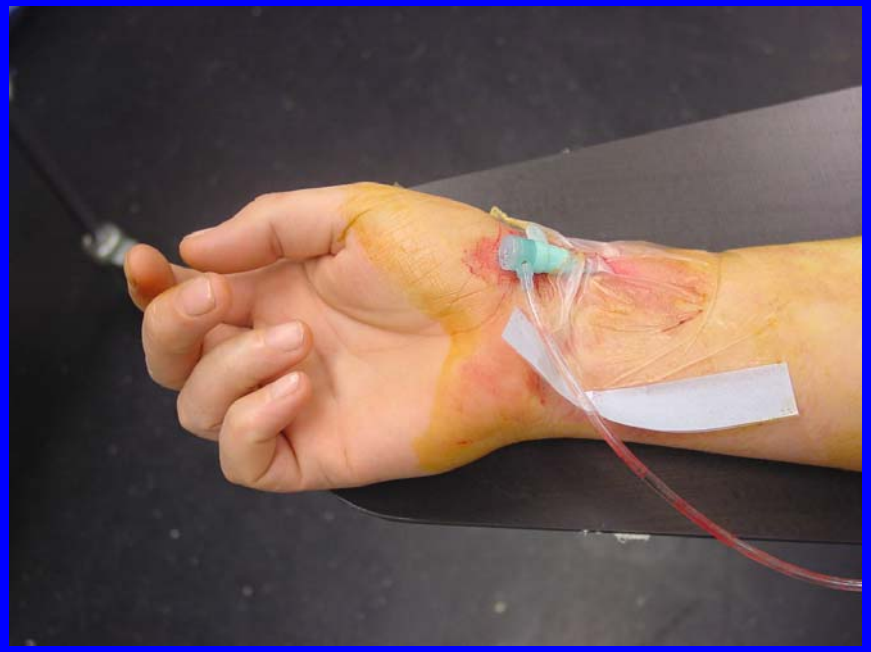

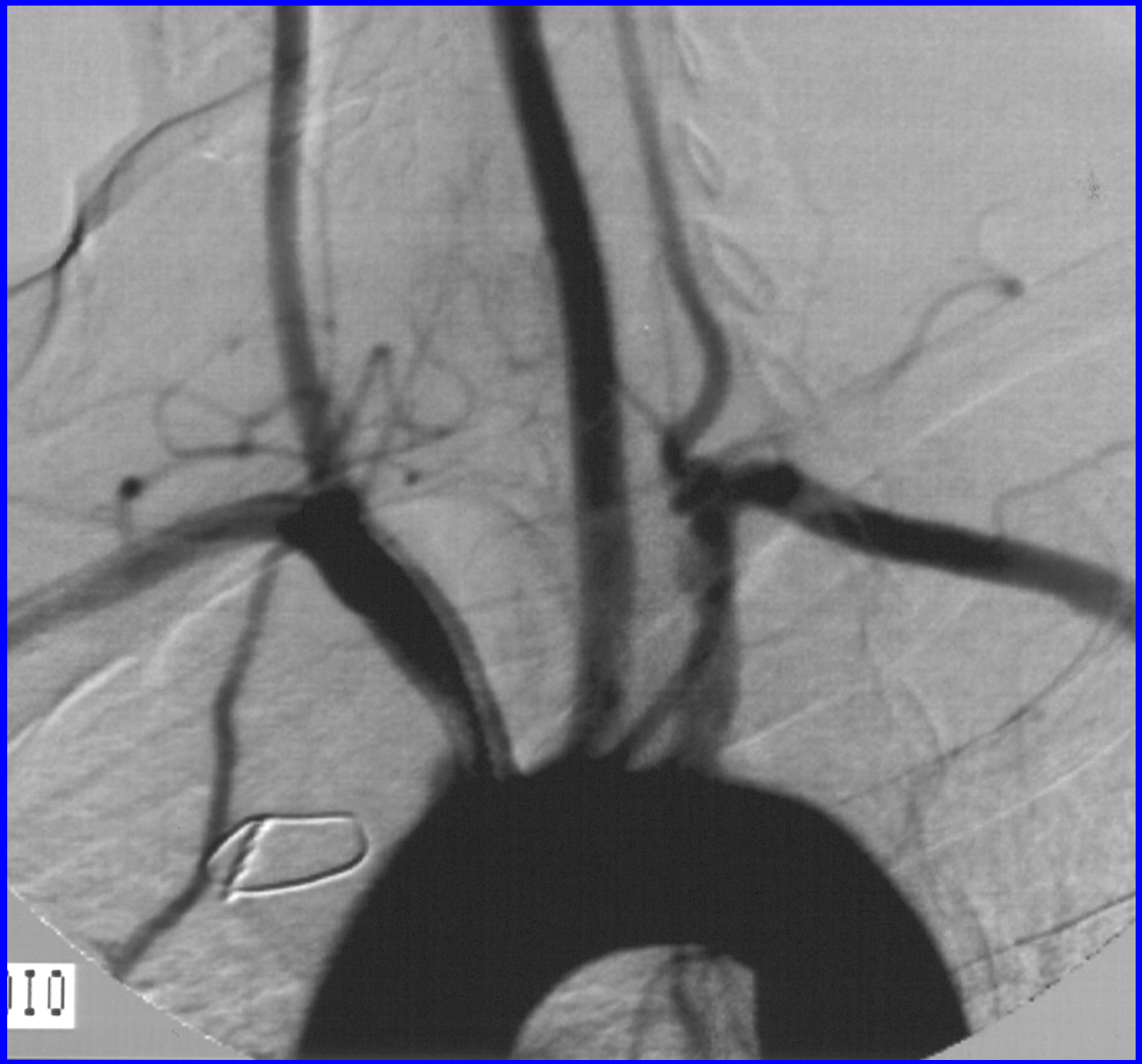

30-MAY-0

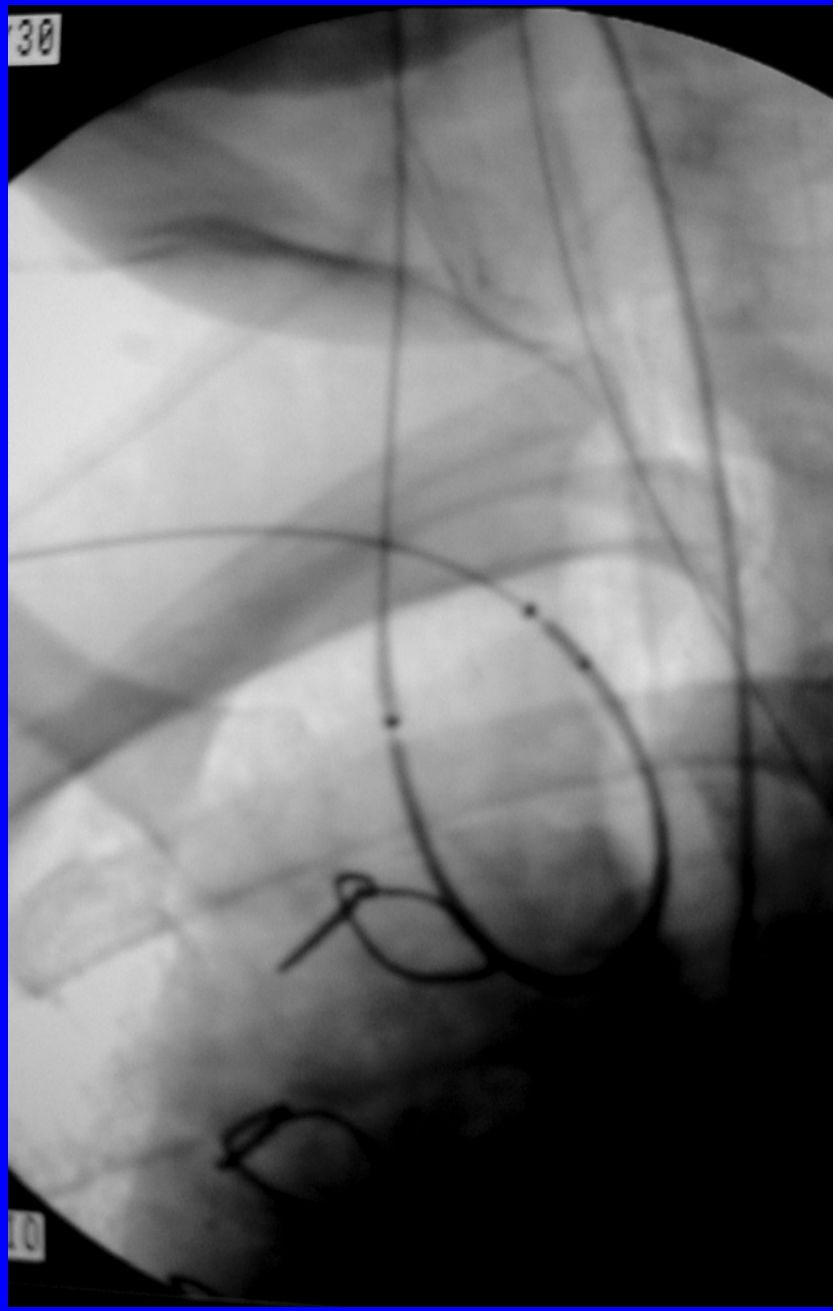
30

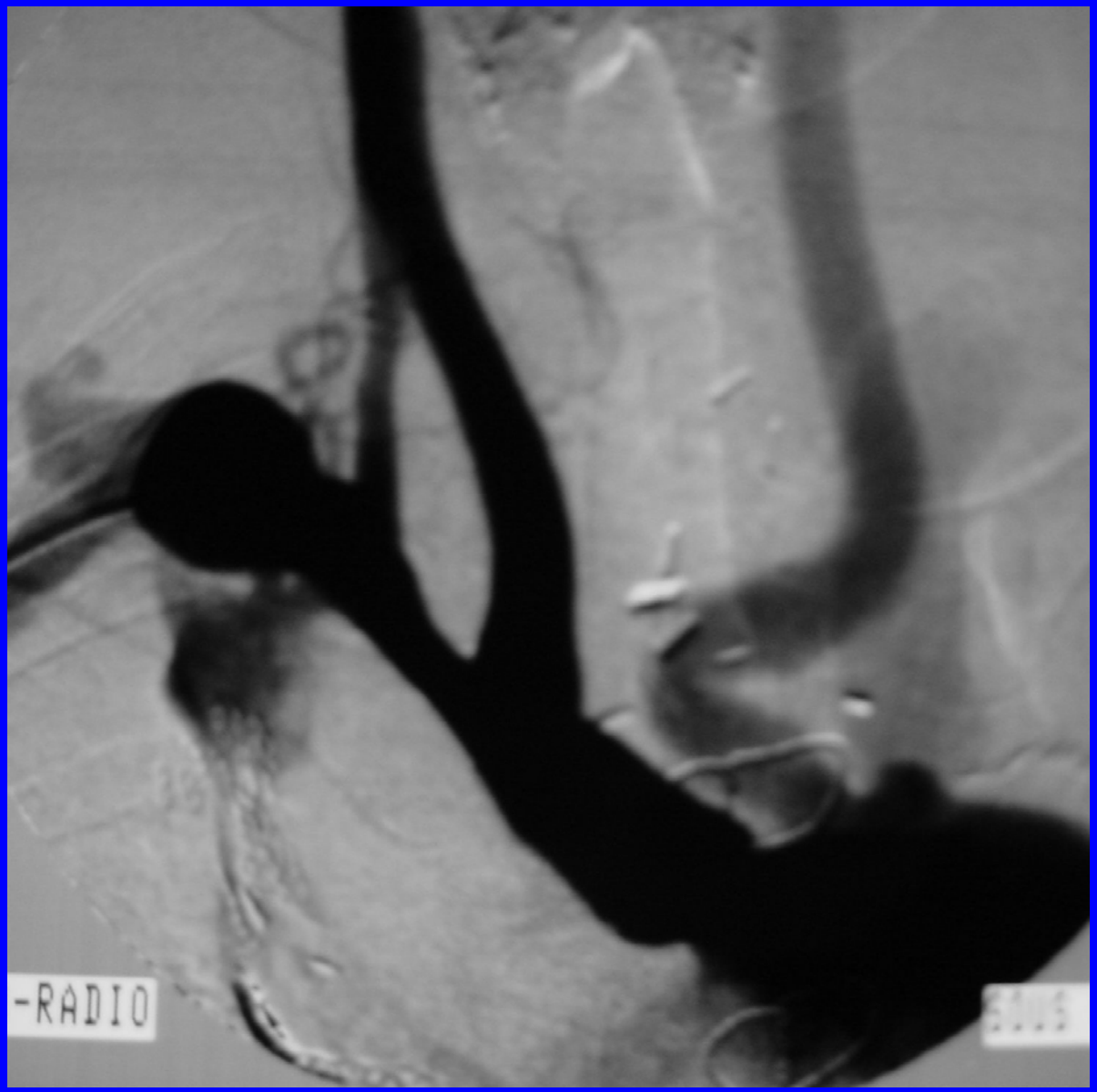
-RADIO

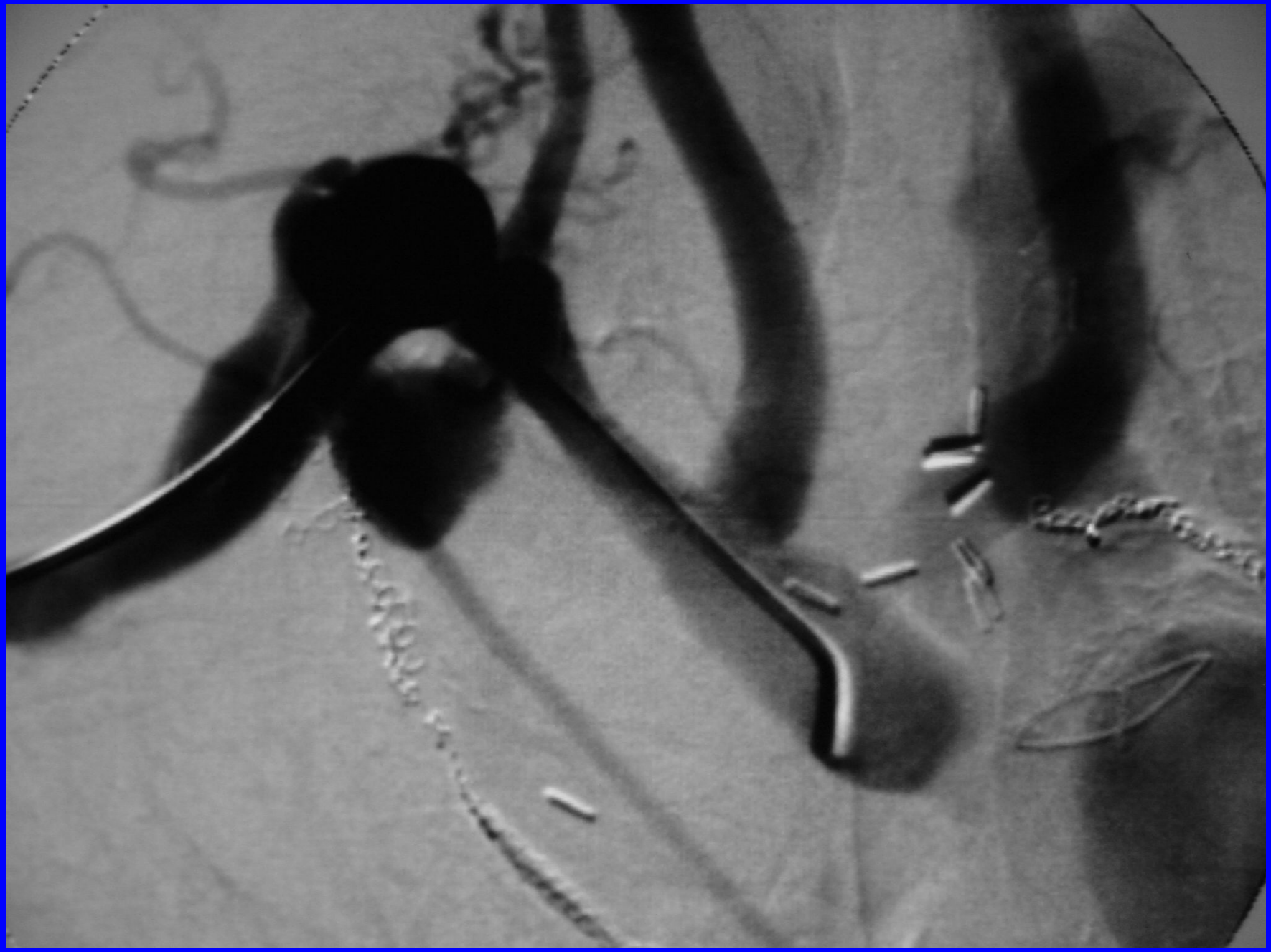

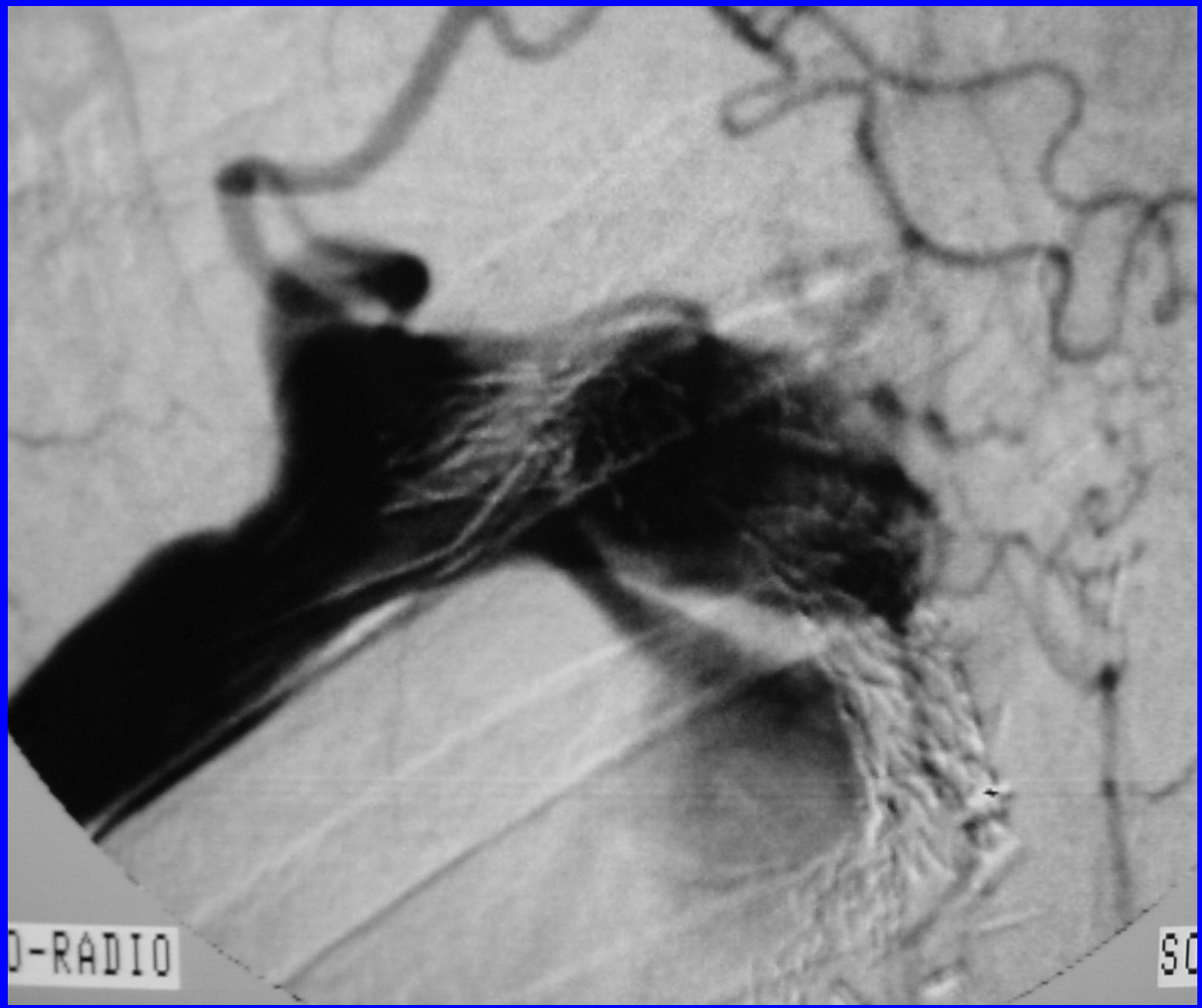
D-RADIO
SC

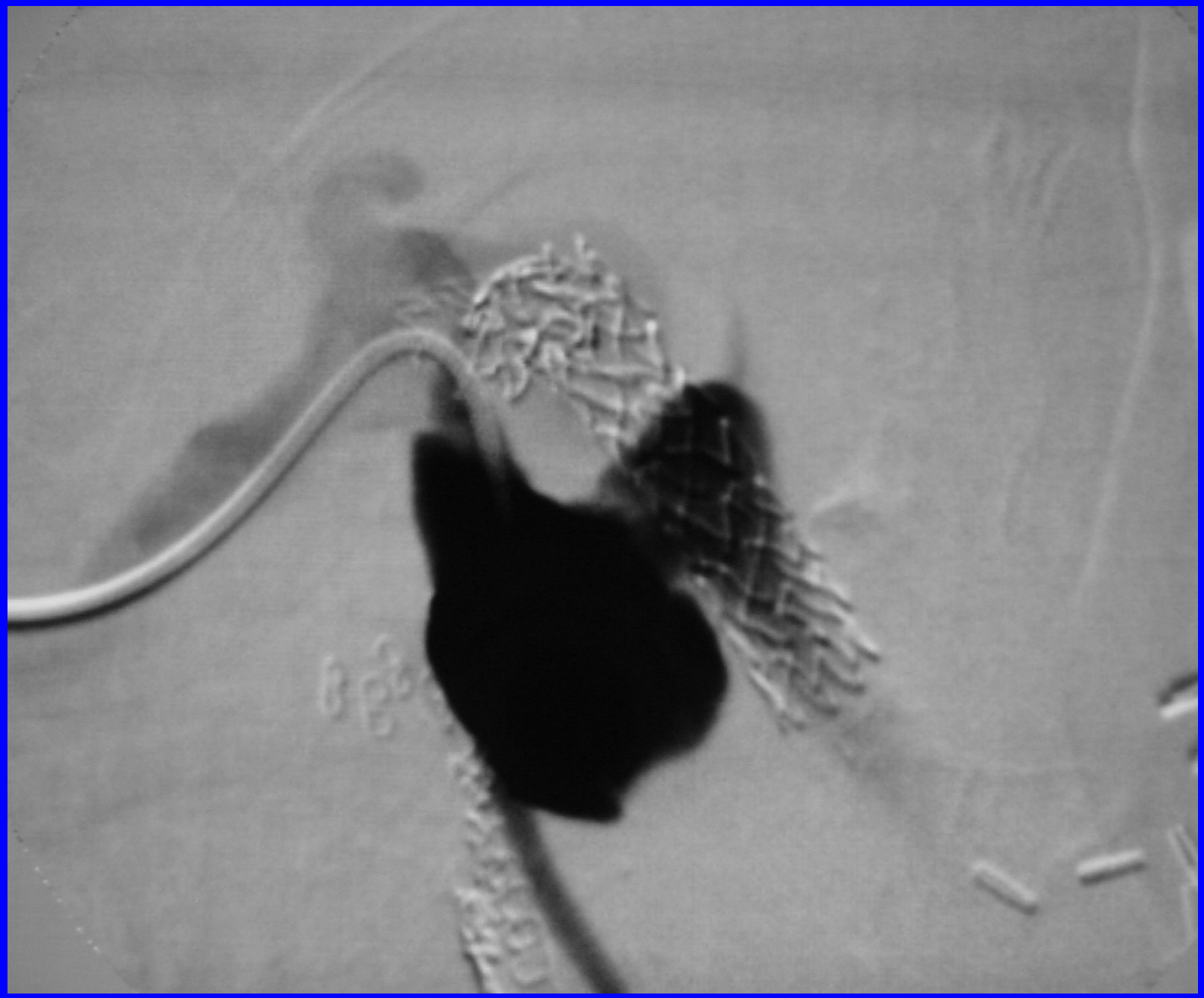

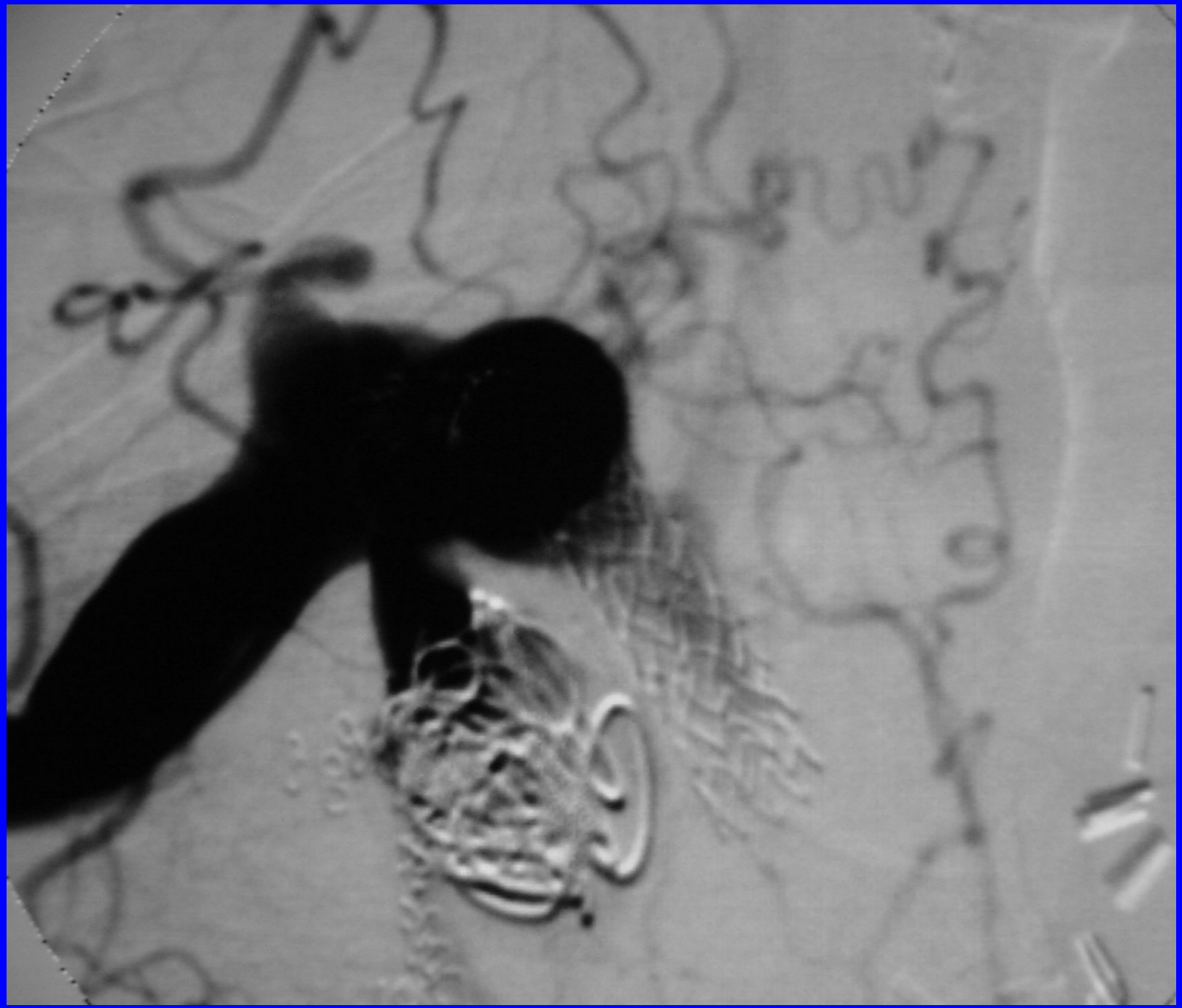

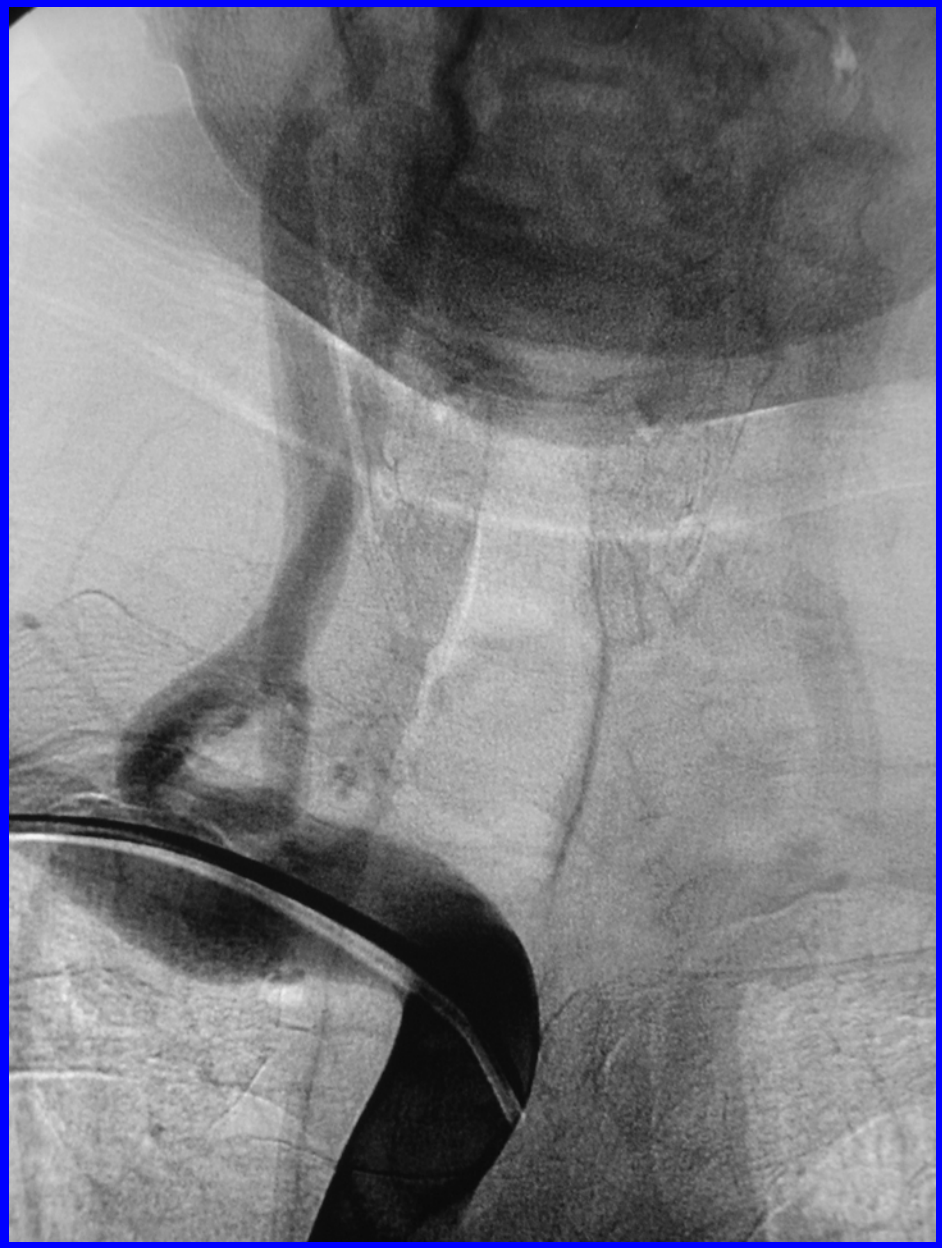

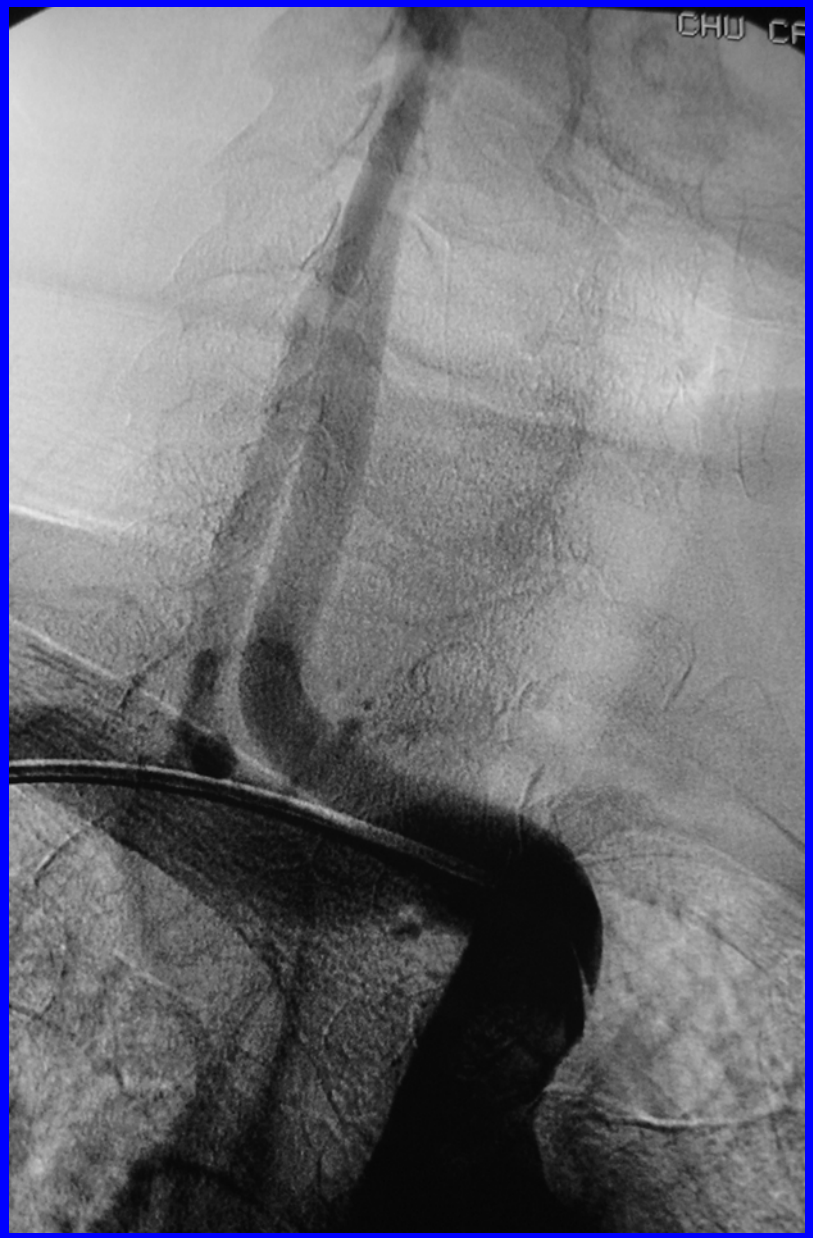
CHU CF

droite
A
R
P
1.5T
OF_GEMS\PFF
I 194

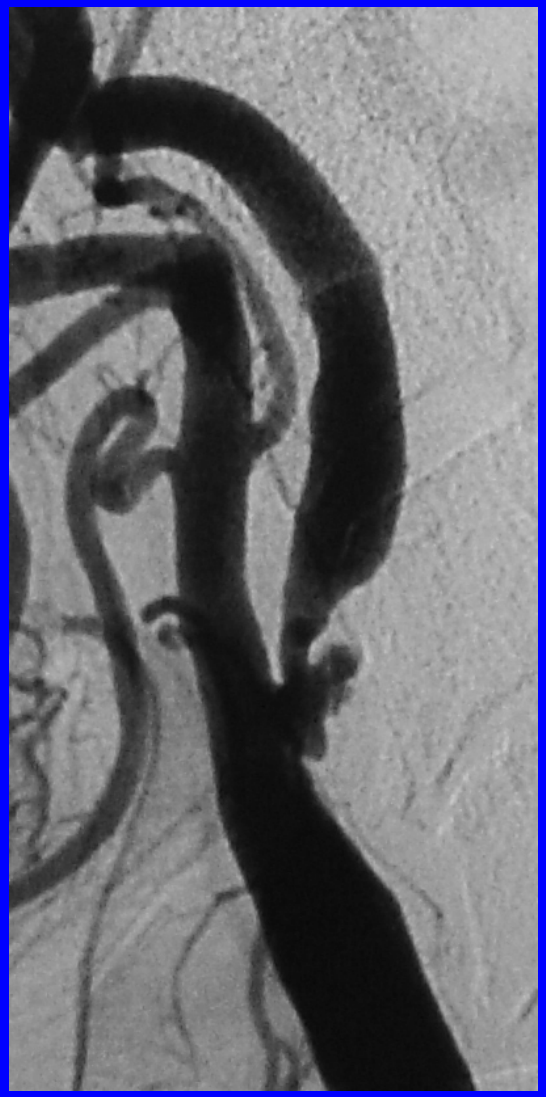

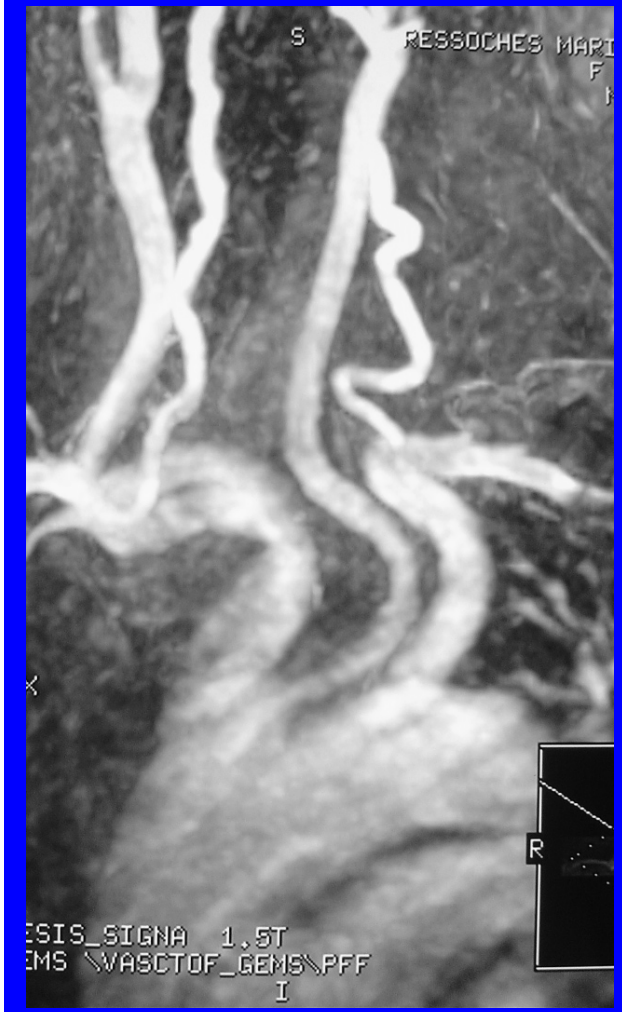
S
RESSOCHES MARI
F
R
ESIS_SIGNA 1.5T
EMS \VASCTOF_GEMS\PFF
I

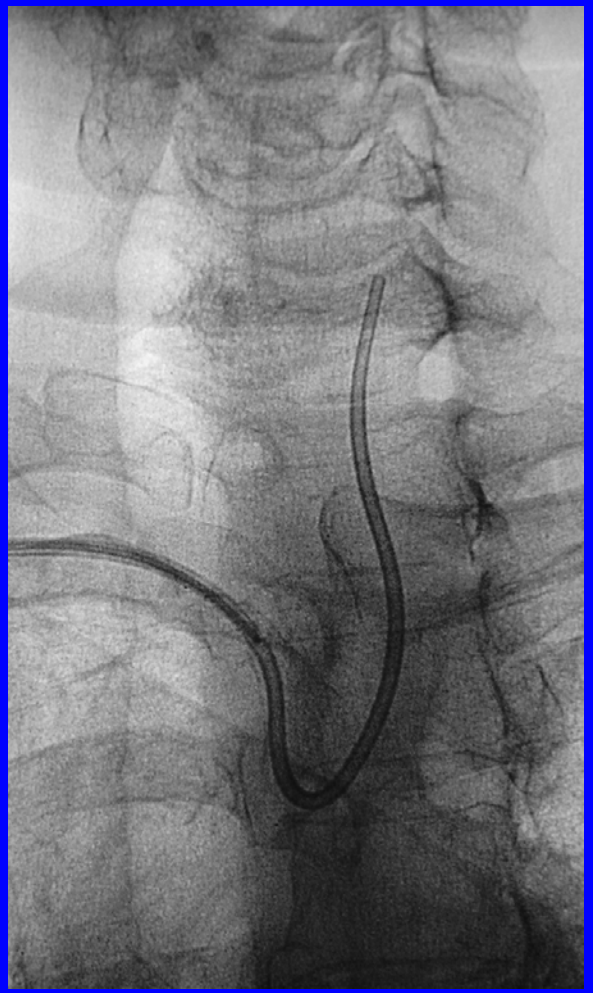

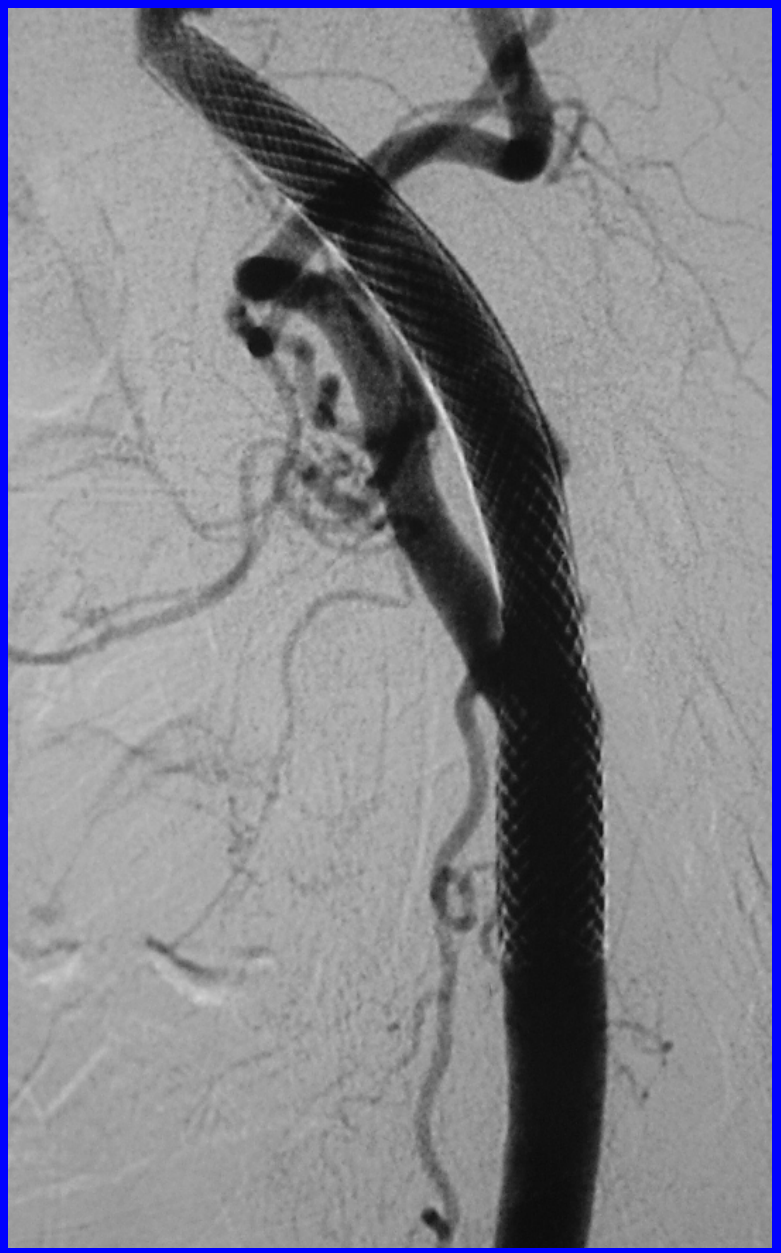

CIG

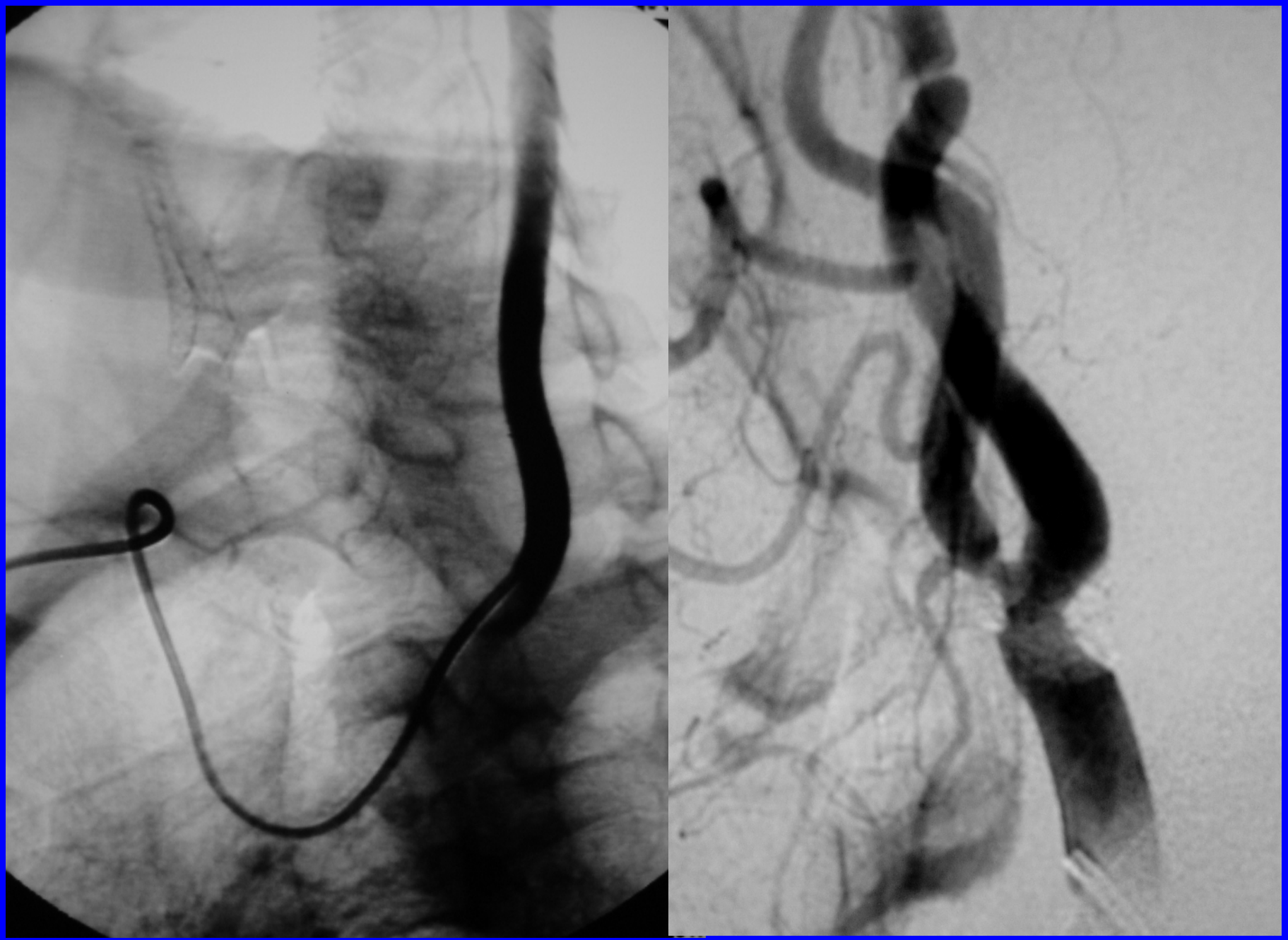

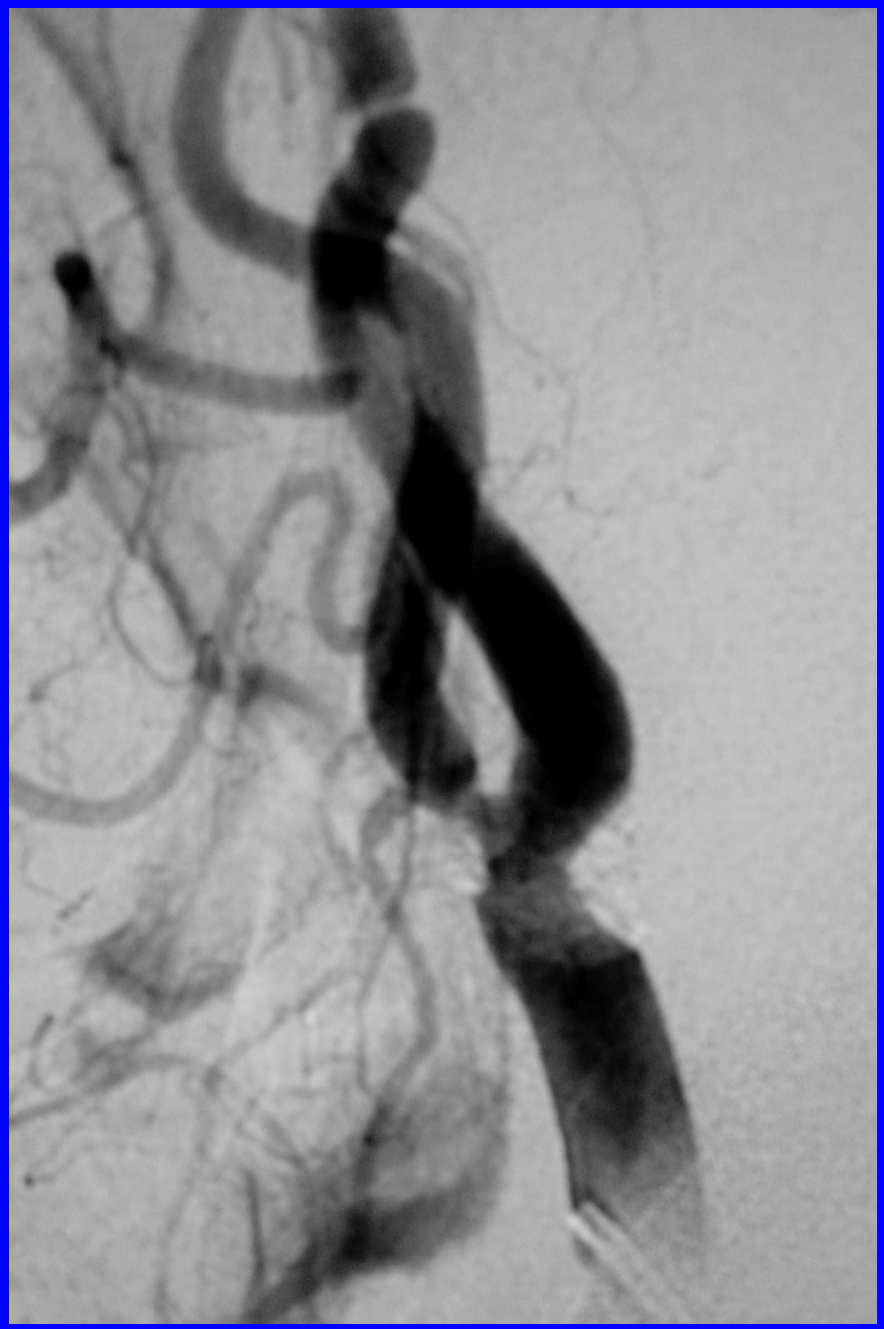

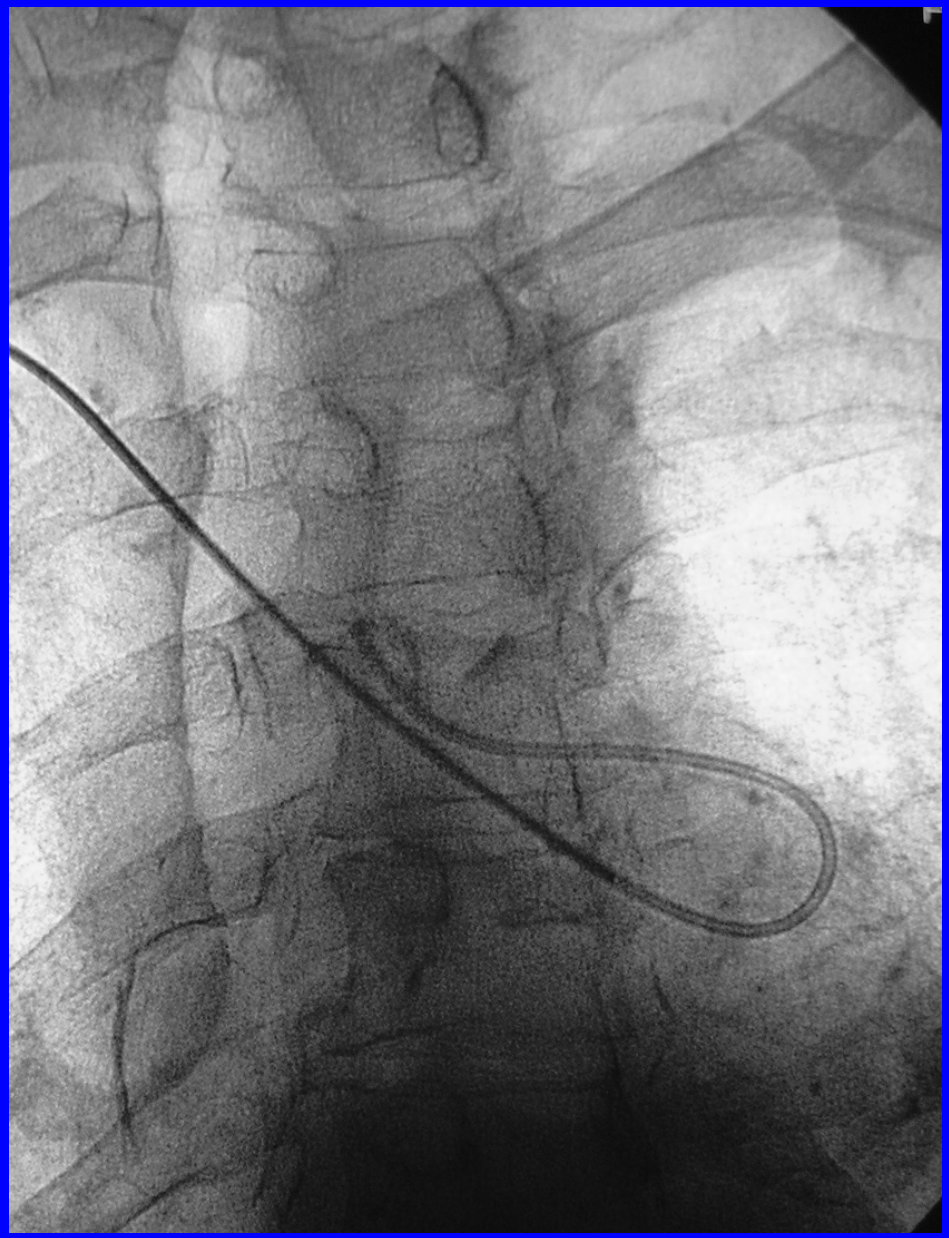

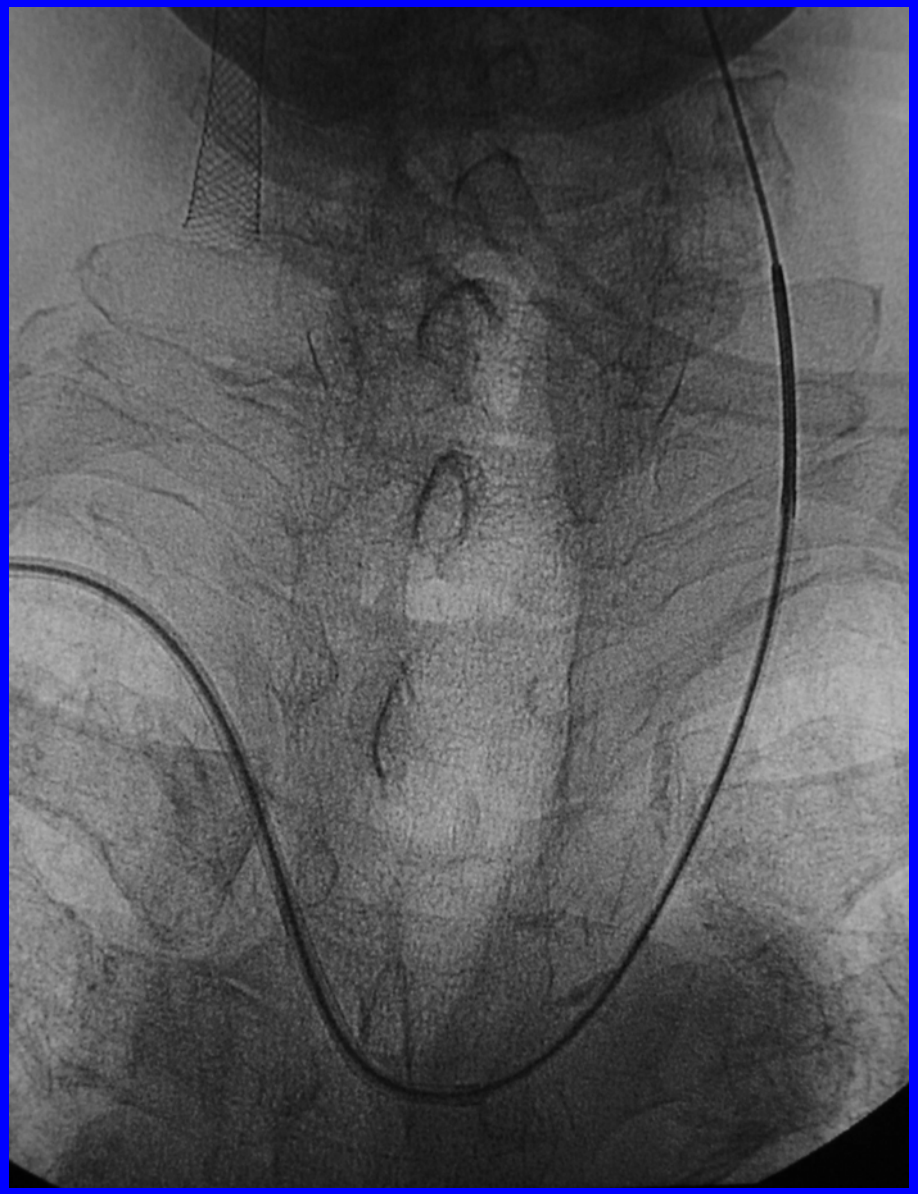

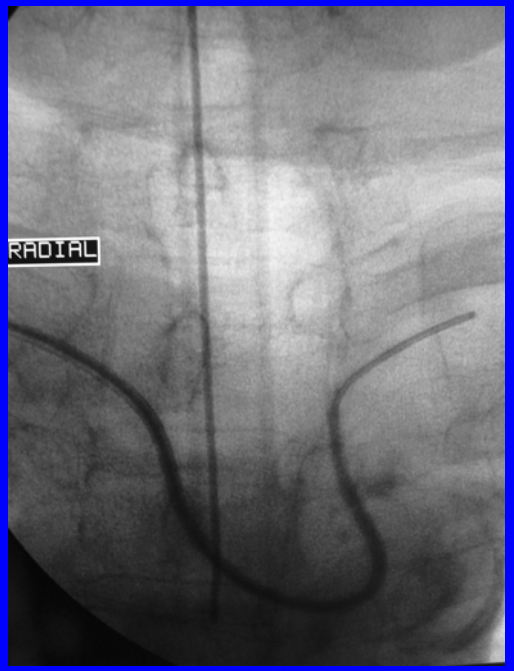
RADIAL

DIAL

C.I.POST-AT